

Khamim UNUSA

by Editor Prominentia

Submission date: 28-Mar-2024 01:39PM (UTC+0700)

Submission ID: 2333572252

File name: Jurnal_unusa.pdf (452.95K)

Word count: 3017

Character count: 16684

Meningioma with Hyperostosis: A Clinical Review up to Acrylic Cranioplasty Reconstruction in 3 Cases

Khamim Tohari¹, Salmon Charles Siahaan^{3*}, Rafi Daffa Dzaky², Raden Roro Shinta Arisanti⁴, Kamila Adam⁵

¹ Department of Neurosurgery, Dr Muhammad Soewandhie Regional General Hospital, Surabaya, Indonesia

² Faculty of Medicine, Universitas Ciputra, Surabaya, Indonesia

³ Department of Obstetrics and Gynecology, Faculty of Medicine, Universitas Ciputra, Surabaya, Indonesia

⁴ Department of Physiology, Faculty of Medicine, Universitas Ciputra, Surabaya, Indonesia

⁵ Department of Psychiatry, Dr Muhammad Soewandhie Regional General Hospital, Surabaya, Indonesia

ARTICLE INFO

Article history:

Received :

January 23, 2024

Received in revised form:

February 23, 2024

Accepted:

March 1, 2024

Keywords:

Meningioma, Hyperostosis,
Meningioma Extracranial,
Cranioplasty Acrylic

ABSTRACT

Meningioma is a type of tumor that commonly occurs in the central nervous system (CNS). Hyperostosis can occur in meningiomas. Hyperostosis is a condition in which the bone surrounding a meningioma thickens abnormally. Although hyperostosis is usually benign, leaving a small portion of bone that still has hyperostosis can increase the risk of recurrence. The case report was carried out by reviewing 3 medical records of meningioma sufferers with hyperostosis.

Medical and Health Science Journal

*Correspondent Author:

Charles.siahaan@ciputra.ac.id

Introduction

Meningiomas are tumors that arise from the meninges. The meninges are membranes that surround the brain, derived from pluripotent mesenchymal cells. The unique ability of these cells to differentiate into various cell types (such as fibrous, osseous, hematopoietic, and vascular) explains why many types of tissue can become meningiomas. Most cases show benign characteristics, with only one to nine percent being categorized as malignant or atypical.¹

Meningiomas are a common form of tumor that occurs within the central nervous system (CNS).

Meningiomas arise from arachnoid cells that are most commonly found near venous sinuses, parasagittal regions, sphenoid wings, middle cranial fossa, cerebellopontine angle, and olfactory sulcus.²

Meningiomas account for approximately 30% of all primary intracranial tumors in adults. The frequency of meningiomas is 83 cases per 100,000 individuals, with a greater predominance in women (with a gender ratio of 2-4:1 favoring women). With increasing age, the incidence of meningiomas is also increases, in the age group 0-19 years at 0.14/100,000, while in the age group 75-84 years at 37.75/100,000.³

Medical And Health Science Journal

Available at <http://journal2.unusa.ac.id/index.php/MHSJ> ; DOI: <https://doi.org/10.33086/mhsj.v7i02.5618>

pISSN 2549-7588. eISSN 2549-75961

In a significant portion (4.5% to 44%) of meningioma cases, the adjacent bone exhibits abnormal thickening, a phenomenon known as hyperostosis. This localized overgrowth is potentially linked to direct tumor cell infiltration into the bone matrix, facilitated by the hypervascular environment surrounding the meningioma.⁴ Despite the often benign nature of hyperostosis associated with meningiomas, incomplete resection, even of a small residual area, can significantly elevate the risk of tumor recurrence. Therefore, achieving complete tumor and osseous resection remains paramount for optimizing long-term recurrence rates and patient quality of life.⁵

This case report was written because meningioma is the most common intracranial tumor in adults with a relatively high incidence of hyperostosis. By discussing this case, it is hoped that it can provide an overview of the clinical to therapeutic aspects of patients with meningioma with hyperostosis, thereby reducing the risk of recurrence and improving patient quality of life.

Cases

Case 1

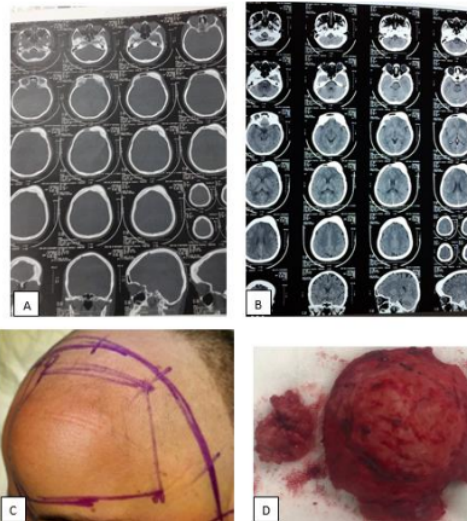


Figure 1. A. CT Scan with Bone Window, B. Non Contrast CT Scan, C. Mass Before Surgery, D. Mass After Surgery

Ms. S, age 39 years, a housewife, with a history of using injectable contraception every 3 months for 15 years, presented with symptom of a lump on her head (Figure 1C), since 5 years ago, followed by intermittent headaches since 1 year ago. The symptom gradually worsened, and seizures were denied. On examination, a mass was found in the left frontal region, one in number, measuring 6cmx4cm, with clear borders, not mobile, and the patient did not feel any tenderness. CT Scan examination (Figure 1A and B) showed a mass with bone thickening (hyperostosis) on the left frontal region. Tumor excision and removal of bone with hyperostosis were performed. Post-operatively, the mass was found to be a primary extracranial meningioma (Figure 1D), the patient's headache symptom improved, and cranioplasty using acrylic was performed 1 month later.

Case 2

Ms. R, age 47 years, a housewife with a history of using injectable contraception every 3 months for 18 years, presented with the main symptom of continuous headache, especially felt in the morning, since 6 months ago. The symptom gradually worsened, and seizures were denied.

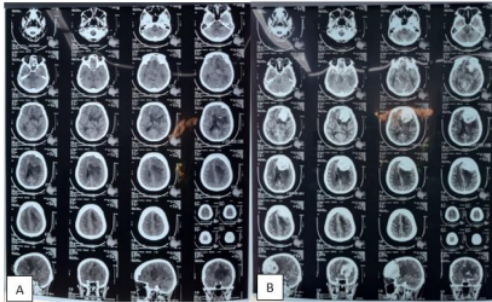


Figure 2. A. Non Contrast CT Scan, B. Contrast CT Scan

CT Scan with contrast showed (Figure 2B) a hyperdense mass image in the left frontal region, and the non-contrast CT Scan (Figure 2A) showed bone thickening (hyperostosis) in the left frontal region. Tumor excision and removal of bone with hyperostosis were performed. Postoperatively, the mass was found to be a meningioma, the patient's headache symptom improved, and cranioplasty using acrylic was performed 1 month later.

Case 3

Ms. P, age 53 years, a housewife with a history of using injectable contraception every 3 months for 20 years, presented with the symptom of recurrent seizures, since 1 year prior to presentation. The symptom was followed by intermittent headaches since 8 months prior to presentation.

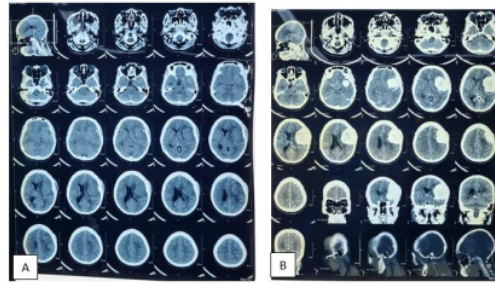


Figure 3. A. Non Contrast CT Scan, B. Contrast CT Scan

CT Scan with contrast (Figure 3B) showed a hyperdense mass image in the left temporoparietal region, and the non-contrast CT Scan (Figure 3A) showed bone thickening (hyperostosis) in the left temporoparietal region. Tumor excision and removal of bone with hyperostosis were performed. Postoperatively, the mass was found to be a meningioma, the patient's symptom improved, the seizure symptom had disappeared and the headache symptom had decreased, and cranioplasty using acrylic was performed 1 month later.

Acrylic Materials for Cranioplasty

All of our patients stayed in the hospital for 3-5 days, after which we began outpatient care.

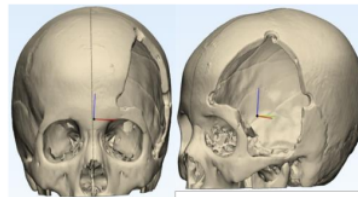


Figure 4. CT before Cranioplasty

The interval between craniectomy and cranioplasty was about one months. The material used was polymethyl methacrylate prostheses.

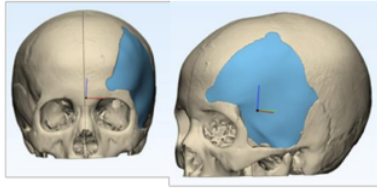


Figure 5. Reconstruction Skull Defect using CAD/CAM (computer-aided design and computer-aided manufacturing) technology



Figure 6. Formation of mold using prosthesis

Cranioplasty preparation started long before the actual surgery. It initiates with a pre-surgery CT scan (Fig. 4) to identify the size and location of the skull defect. Subsequently, we employ CAD/CAM (computer-aided design and computer-aided manufacturing) technology to reconstruct the defect, crafting a customized prosthesis for each patient (Fig. 5). This prosthesis is then fabricated using a 3D printer.

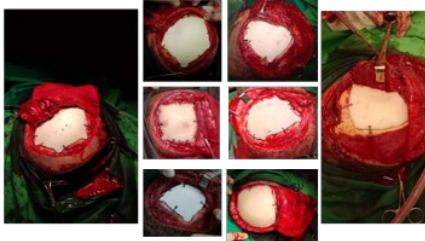


Figure 7. Cranioplasty using Acrylic

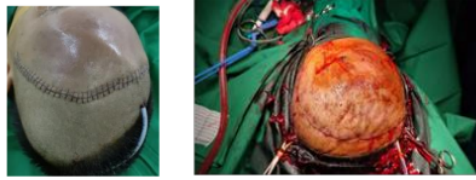


Figure 8. After undergoing cranioplasty surgery, the patient's skull shape returned to normal.

On the surgery day, all patients are administered perioperative antibiotics. The prosthesis is utilized to shape a mold, which undergoes sterilization (Fig. 6) and is employed during the surgery to create a patient-specific implant (Fig. 7). Following the cranioplasty procedure, the patient's skull shape was restored to its original state (Fig 8).

Discussion

This case report presents three female patients, all exceeding 39 years old and sharing the unique risk factor of long-term (over 15 years) injectable contraception use every 3 months. This finding aligns with existing research demonstrating a higher incidence of meningioma in women over 40 (18.69 per 100,000) compared to young women (0.16 per 100,000) and in women overall compared to men (2:1 ratio). This sex-based disparity may be linked to the known influence of sex hormones, thought to affect meningioma development since the late 1920s.⁷ Growing evidence suggests that exogenous hormones, such as those used in hormonal contraception, can significantly increase the risk of meningioma development. Premenopausal women using these hormones face a potential 2.48-fold higher risk compared to postmenopausal women with a history of hormone use. This association appears to be driven by long-term exposure to exogenous progesterone, a common component of many contraceptives. The

mechanism behind this link may involve the progesterone receptor's interaction with coactivators and/or corepressor proteins, influencing gene expression patterns related to tumor development.⁸

Headache was the symptom reported by all patients in this case report. Patient 1 had headache for 1 year before admission to the hospital and also had a symptom of a mass in the left frontal region. Patient 2 had headache for 6 months before admission to the hospital, while patient 3 had headache for 8 months before admission to the hospital. Patient 3 was the only patient with a symptom of seizures in this study. These data are consistent with other studies that show that 60.5% (1,119 of 1,852 patients) of meningioma patients present with headache. Whereas, seizure can occur in 17.4% (323 of 1,852 patients). The time between the onset of headache in patients until the patient is diagnosed ranges from 6 to 24 months.⁹ Brain tumor headaches often involve pressure and nerve irritation. These headaches disappear in most patients after surgery, especially for larger tumor. This improvement likely happens because removing a large tumor reduces pressure inside the skull, easing the headache.¹⁰

In the presented case report, the seizures experienced by patient 3 can be directly attributed to the unfortunate placement of the tumor within their temporoparietal region. This specific area of the brain, temporal lobes, harbors an elevated risk for triggering seizures in individuals with meningiomas.¹¹

Primary extracranial meningioma is a rare form of meningioma. This occurred in patient 1 of the case report, where the patient had an extracranial meningioma with a mass appearance

on the left frontal region. Extracranial meningioma is divided into primary and secondary. Primary indicates the absence of intracranial lesions, while secondary indicates the presence of intracranial meningioma lesions followed by extracranial lesions. The location of occurrence is often under the scalp. Extracranial meningioma is difficult to diagnose using only CT scan, because it will only appear as a hyperdense mass with occasional hyperostosis. MRI and angiography also do not show much difference with the surrounding tissues, so the definite confirmation is through anatomical pathology biopsy.¹² Extracranial meningioma can occur due to the descent of arachnoid cells in the protective layer of cranial nerves that migrate out of the intracranial during skull formation.¹³

All patients in this case report study had hyperostosis. Hyperostosis is a condition in which the bone surrounding the meningioma undergoes abnormal thickening.⁴ Hyperostosis of the bone adjacent to meningioma, which can be observed on CT with bone window, has been well described, with many reports discussing the possible causes. A prominent theory is that bone invasion by tumor cells/tissue causes hyperostosis. This is supported by histopathological studies that have clearly shown tumor tissue invasion into adjacent bone in areas with hyperostosis, which is thought to be associated with strong somatostatin receptor subtype 2A (SSR2A) reactivity.¹⁴ In cases of suspected meningioma with bone invasion, maximal resection of the adjacent bone will be the preferred option, thus requiring craniectomy.¹⁵

Craniectomy disrupts the brain's delicate balance, affecting pressure, CSF flow, and blood circulation following the Monro-Kellie hypothesis.

This can lead to potential complications like hydrocephalus and sunken flap syndrome.¹⁶

Cranioplasty is a surgical procedure that aims to repair acquired or congenital cranial defects.¹⁷ Cranioplasty has a dual function, namely as a protector of cerebral structures and as a therapeutic intervention to manage changes in cerebrospinal fluid (CSF), blood circulation, and brain metabolic needs. In addition, it can offer aesthetic benefits by reconstructing cranial bone deformities.¹⁸

In this study, acrylic was chosen as a cranioplasty material because of its low cost and good biocompatibility, which is consistent with recent research.¹⁹ Although acrylic cranioplasty is generally considered a safe method, its complication rates are comparable to, although not superior to, other synthetic cranioplasty techniques.²⁰⁻²¹ In fact, recent studies have shown that acrylic has a lower complication rate of infection than titanium mesh.²²

The time interval between craniotomy and cranioplasty for patients in this study was one month, which was done to minimize the risk of infection and seizures after surgery. Studies have shown that infection is most commonly reported in the first 14 days after craniotomy, and the risk of seizure is observed to increase after 90 days.²³ Other studies have found that functional outcomes are better for cranioplasty performed at a time of less than 7 weeks or at 7-12 weeks compared to that performed at more than 12 weeks.²⁴

Conclusion

Meningioma is a tumor that originates from the meninges. Meningioma is the most common intracranial tumor in adults. Common symptoms

that patients often experience are headache and seizures. Meningioma can invade the surrounding bone, causing thickening of the bone called hyperostosis. Bone hyperostosis adjacent to meningioma can be observed on CT scan with bone window. In meningioma with hyperostosis, it is necessary to perform meningioma excision and remove all of invaded bone, thereby reducing the recurrence rate, and can improve the quality of life of patients.

Conflict of Interest

The author started there is no conflict of interest.

References

1. Rothschild, B. M. Recognizing and distinguishing the phenomenon referred to as meningioma. *Anatomia*, 2022, 1(1): 107-118.
2. Lyndon, D., Lansley, J. A., Evanson, J., & Krishnan, A. S. Dural masses: meningiomas and their mimics. *Insights into imaging*, 2019, 10(1): 1-22.
3. Zhao, L., Zhao, W., Hou, Y., Wen, C., Wang, J., Wu, P., & Guo, Z. An overview of managements in meningiomas. *Frontiers in oncology*, 2020, 10: 1523.
4. Di Cristofori, A., Del Bene, M., Locatelli, M., Boggio, F., Ercoli, G., Ferrero, S., & Del Gobbo, A. Meningioma and bone hyperostosis: expression of bone stimulating factors and review of the literature. *World Neurosurgery*, 2018, 115: e774-e781.

5. Fathalla, H., Tawab, M. G. A., & El-Fiki, A. Extent of hyperostotic bone resection in convexity meningioma to achieve pathologically free margins. *Journal of Korean Neurosurgical Society*, 2020, 63(6): 821-826.
6. Ostrom, Q. T., Cioffi, G., Gittleman, H., Patil, N., Waite, K., Kruchko, C., & Barnholtz-Sloan, J. S. CBTRUS statistical report: primary brain and other central nervous system tumors diagnosed in the United States in 2012–2016. *Neuro-oncology*, 2019, 21(5): 1-100.
7. Lin, D. D., Lin, J. L., Deng, X. Y., Li, W., Li, D. D., Yin, B., & Sheng, H. S. Trends in intracranial meningioma incidence in the United States, 2004-2015. *Cancer medicine*, 2019, 8(14): 6458-6467.
8. Ichwan, S., Santoso, F., Aman, R. A., Tandian, D., Fachniadin, A., & Nugroho, S. W. Estrogen and progesterone in meningioma: Bridging the gap of knowledge. *Neurology Asia*, 2023, 28(1).
9. Nassiri, F., Suppiah, S., Wang, J. Z., Badhiwala, J. H., Juraschka, K., Meng, Y., & Zadeh, G. How to live with a meningioma: experiences, symptoms, and challenges reported by patients. *Neuro-Oncology Advances*, 2020, 2(1): 86-94.
10. Guenther, F., Swozil, F., Heber, S., Buchfelder, M., Messlinger, K., & Fischer, M. J. Pre-and postoperative headache in patients with meningioma. *Cephalalgia*, 2019, 39(4): 533-543.
11. Harward, S. C., Rolston, J. D., & Englot, D. J. Seizures in meningioma. *Handbook of Clinical Neurology*, 2020, 170: 187-200.
12. Kim, C. M., Jeon, Y. R., Kim, Y. J., & Chung, S. Primary extracranial meningioma presenting as a forehead mass. *Archives of Craniofacial Surgery*, 2018, 19(1): 55.
13. Buetow, M. P., Buetow, P. C., & Smirniotopoulos, J. G. Typical, atypical, and misleading features in meningioma. *Radiographics*, 1991, 11(6): 1087-1106.
14. Takase, H., & Yamamoto, T. Bone invasive meningioma: recent advances and therapeutic perspectives. *Frontiers in Oncology*, 2022, 12: 895374.
15. Meling, T. R., Da Broi, M., Scheie, D., Helseth, E., & Smoll, N. R. Meningioma surgery—are we making progress?. *World neurosurgery*, 2019, 125: e205-e213.
16. Tel, A., Tuniz, F., Fabbro, S., Sembronio, S., Costa, F., & Robiony, M. Computer-guided in-house cranioplasty: establishing a novel standard for cranial reconstruction and proposal of an updated protocol. *Journal of Oral and Maxillofacial Surgery*, 2020, 78(12): 2297. e1-2297. e16.
17. Thakur, A., Chauhan, D., Viswambaran, M., Yadav, R. K., & Sharma, D. Rapid prototyping technology for cranioplasty: A case series. *The Journal of the Indian Prosthodontic Society*, 2019, 19(2): 184.

18. Alkhaibary, A., Alharbi, A., Alnefaie, N., Almubarak, A. O., Aloraidi, A., & Khairy, S. Cranioplasty: a comprehensive review of the history, materials, surgical aspects, and complications. *World neurosurgery*, 2020, 139: 445-452.
19. Liu, L., Lu, S. T., Liu, A. H., Hou, W. B., Cao, W. R., Zhou, C., & Zhang, H. J. Comparison of complications in cranioplasty with various materials: a systematic review and meta-analysis. *British journal of neurosurgery*, 2020, 34(4): 388-396.
20. Jaber, J., Gambrell, K., Tiwana, P., Madden, C., & Finn, R. Long-term clinical outcome analysis of poly-methyl-methacrylate cranioplasty for large skull defects. *Journal of Oral and Maxillofacial Surgery*, 2013, 71(2): e81-e88.
21. Lee, S. C., Wu, C. T., Lee, S. T., & Chen, P. J. Cranioplasty using polymethyl methacrylate prostheses. *Journal of clinical neuroscience*, 2009, 16(1): 56-63.
22. Millward, C. P., Doherty, J. A., Mustafa, M. A., Humphries, T. J., Islim, A. I., Richardson, G. E., & McMahon, C. J. Cranioplasty with hydroxyapatite or acrylic is associated with a reduced risk of all-cause and infection-associated explantation. *British Journal of Neurosurgery*, 2022, 36(3): 385-393.
23. Iaccarino, C., Koliass, A. G., Roumy, L. G., Fountas, K., & Adeleye, A. O. Cranioplasty following decompressive craniectomy. *Frontiers in neurology*, 2020, 10: 1357.
24. Archavlis, E., & Carvi Y Nievas, M. The impact of timing of cranioplasty in patients with large cranial defects after decompressive hemicraniectomy. *Acta Neurochirurgica*, 2012, 154: 1055-1062.

Khamim UNUSA

ORIGINALITY REPORT

12%

SIMILARITY INDEX

10%

INTERNET SOURCES

7%

PUBLICATIONS

%

STUDENT PAPERS

MATCH ALL SOURCES (ONLY SELECTED SOURCE PRINTED)

3%

★ www.frontiersin.org

Internet Source

Exclude quotes Off

Exclude matches Off

Exclude bibliography On